



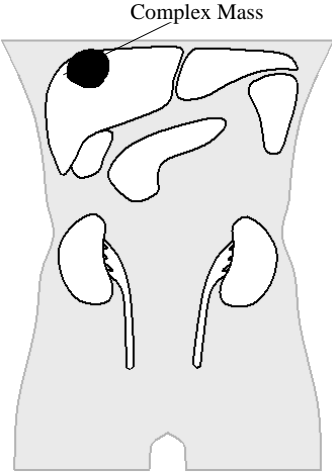
# Memorial Medical Center



## Abdominal Ultrasound Report

<b>Patient Name:</b>	Donahue, Jack	<b>Gender:</b>	M	<b>Patient ID:</b>	12345
<b>Study Date:</b>	3/1/2014	<b>Priority:</b>	ROUTINE	<b>Referring MD:</b>	Benjamin Shah, MD
<b>Indications:</b>	Abnormal labs	<b>Technologist:</b>	Seth Marks, RDCS	<b>DOB, Age:</b>	10/2/1963, 50 yr
<b>History/Clinical:</b>	Cancer				
<b>Procedure:</b>	Limited - Liver and Biliary				

<b>Liver:</b>	A complex mass is identified within the right lobe of the liver.			
	Length	11.5 cm	Height	5.84 cm
	Width	6.4 cm	Vol	429.824 cm <sup>3</sup>
<b>Gallbladder:</b>	The gallbladder appears unremarkable. No focal abnormality noted.			
	Length	6 cm	Wall	2.2 cm
	CBD	0.5 cm		
<b>Spleen:</b>	The spleen appears unremarkable. No focal abnormality noted.			
	Length	9.9 cm	Height	4.5 cm
	Width	5.2 cm	Vol	231.66 cm <sup>3</sup>

<p><b>Abdominal</b></p>  <p>Complex Mass</p>	<p><b>Images</b></p>  <p>Abd Gen C9-2 10Hz RS 2D 64% Dyn R 55 P Low HGen</p> <p>TISO.4 MI 1.1 C 3:48 C 3:41 M3 24cm</p>
--	---

**Impression**

Complex mass seen in the right lobe of the liver suspect for hepatocellular carcinoma. Recommend CT to confirm.

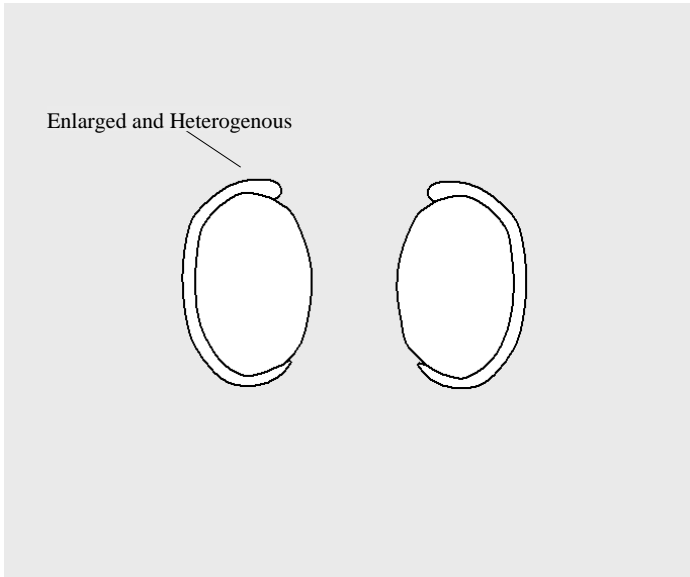
\_\_\_\_\_  
Anna Hong, MD



## Testicular Ultrasound Report

<b>Patient Name:</b>	Donahue, Jack	<b>Gender:</b>	M	<b>Patient ID:</b>	12345
<b>Study Date:</b>	11/12/2015			<b>Priority:</b>	ROUTINE
<b>ICD9:</b>	88.7			<b>Referring MD:</b>	John Martinez, MD
				<b>Technologist:</b>	Blake Robertson, RDCS
				<b>DOB, Age:</b>	10/2/1963, 52 yr
				<b>CPT4:</b>	76870
<b>Indications:</b>	Swelling				
<b>History/Clinical:</b>	History of RLE Sarcoma, Acute Scrotal Swelling				
<b>Previous Study:</b>	Date: 03/01/2014				

<b>Rt Testicle:</b>	The right testicle is unremarkable. No focal abnormalities noted.				
	Length	4 cm	Height	3 cm	
	Width	2.5 cm	Vol	15.708 cm <sup>3</sup>	
<b>Rt Epididymis:</b>	The right epididymis is heterogeneous and enlarged in size.				
	Length	2.2 cm	Height	3.5 cm	
	Width	3.2 cm			
<b>Lt Testicle:</b>	The left testicle is unremarkable. No focal abnormalities noted. No hydrocele noted.				
	Length	4.1 cm	Height	3.2 cm	
	Width	3 cm	Vol	20.609 cm <sup>3</sup>	
<b>Lt Epididymis:</b>	The left epididymis is unremarkable. No focal abnormalities noted.				

<p><b>Testicular</b></p> 	<p><b>Impression</b></p> <ol style="list-style-type: none"> <li>1. Normal-sized testicles are noted bilaterally.</li> <li>2. Bilaterally no evidence of torsion.</li> <li>3. No evidence of mass or cyst is seen bilaterally.</li> <li>4. The Rt epididymis is enlarged with increased vascularity indicating acute epididymitis.</li> <li>5. There is a moderate Rt hydrocele.</li> </ol> <p>_____  <b>Jared Franklin, MD</b></p>
--	--



